

# Lung parenchymal injury and its frequency in blunt thoracic trauma: the diagnostic value of chest radiography and thoracic CT

Muzaffer Elmalı, Ahmet Baydın, Mehmet Selim Nural, Bora Arslan, Meltem Ceyhan, Nevzat Gürmen

## PURPOSE

The aims of this study were to determine the value of chest radiography in diagnosing lung parenchymal injury in patients with thoracic trauma, and to evaluate the frequency of lung parenchymal injury by using thoracic computed tomography (CT).

## MATERIALS AND METHODS

Between January 2005 and June 2006, we retrospectively evaluated the anteroposterior chest radiographs and thoracic CTs of 60 patients that presented to our emergency department and were hospitalized due to multi-organ trauma.

## RESULTS

Chest radiography revealed parenchymal injury in 32 of the patients, while thoracic CT confirmed parenchymal injury in only 27 of these 32 patients. Chest radiographs did not reveal any parenchymal injury in 28 of the patients, whereas thoracic CT detected parenchymal injury in 12 of these 28 patients. Thoracic CT results were accepted as the gold standard in the evaluation of patients with chest trauma and showed that the sensitivity, specificity, positive predictive value, and negative predictive value of chest radiography in determining parenchymal injury were 69%, 76%, 84%, and 57%, respectively. In addition, thoracic CT revealed that 65% of the patients with blunt thoracic trauma suffered parenchymal injury.

## CONCLUSION

The sensitivity of anteroposterior chest radiography in identifying lung parenchymal injury was low, with a high false negative rate; therefore, we think that early evaluation with thoracic CT is extremely helpful in the diagnosis and treatment of patients with thoracic trauma, adding to the cooperative work that exists between radiologists and emergency physicians.

**Key words:** • blunt thorax trauma • chest radiography • computed tomography, thoracic • lung contusion • lung injury

**T**horacic traumas are becoming more frequent every day, especially as a consequence of motor vehicle accidents. Trauma is the most common cause of death during the first 3 decades of life and deaths due to thoracic trauma account for 25% of all trauma deaths (1–3).

The first-line radiological examination in patients with thoracic trauma is chest X-ray. The assessment of X-rays obtained in emergency conditions may be limited by some negative factors due to the patient's condition. In particular, X-rays taken just a few hours after the occurrence of blunt trauma may not demonstrate the injury. In cases of lung parenchymal contusion, hematoma, or laceration, morbidity and mortality increase significantly in those with thoracic trauma. For this reason, early detection of lung parenchymal injuries is critically important for revealing the dispersion and accompanying pathologies, and for treatment planning. Mortality rates can be reduced by emergency radiologists experienced in chest radiography, and the fast and effective use of other radiologic modalities, with good cooperation between radiologists and emergency physicians.

The aims of this study were to evaluate the diagnostic value of chest X-rays in detecting lung parenchymal injuries after blunt thoracic trauma, and to reveal the frequency of parenchymal injuries using thoracic computed tomography (CT).

## Materials and methods

Anteroposterior chest radiographs and axial CT images of 65 patients that presented to the emergency room and were subsequently hospitalized for multiple trauma between January 2005 and June 2006 were evaluated retrospectively. Five patients that had CT imaging performed >1 h after chest X-ray, had penetrating traumas, or had chest X-rays that did not qualify for parenchymal assessment were excluded from the study. Injuries in the study population were caused by motor vehicle accidents, falling from a height, direct trauma, and occupational accidents. Mean age of the patients was 43 years (range, 16–85 years), 48 were male, and 12 were female. Chest radiographs were obtained immediately after presentation to the emergency room and thoracic CTs were taken within 1 h of chest X-rays, based on patient respiratory system findings. Chest radiographs of the trauma patients were routinely obtained in the supine anteroposterior position. Thoracic CT images were taken using a spiral CT (Xpres/GX, Toshiba, Japan) and with intravenous administration of 100 ml of iodine-containing non-ionic contrast medium, without using an automatic injector. Technical parameters were as follows: section thickness, 7 mm; table speed, 7 mm (pitch, 1); kVp, 120; mAs, 150.

Assessments were made by 2 radiologists experienced in chest radiology, and final decisions were made by consensus. An abnormal increase

From the Departments of Radiology (M.E. ✉ [muzafel@yahoo.com.tr](mailto:muzafel@yahoo.com.tr), M.S.N., M.C., N.G.), and Emergency Medicine (A.B., B.A.), 19 Mayıs University School of Medicine, Samsun, Turkey.

Received 12 December 2006; revision requested 14 May 2007; revision received 28 May 2007; accepted 1 August 2007.

in parenchymal intensity was considered parenchymal injury. In thoracic CT, parenchymal injuries were classified as follows: Contusion: alveolar or ground-glass parenchymal density increases, which were tending to coalesce; laceration: ripped or cavity-shaped air spaces that were separated from or located within the lung parenchymal contusion area; hematoma: homogenous hyperdense areas close to blood density that were smooth bordered and tended to be spherical. In addition to parenchymal injury findings in thoracic CT, accompanying extra-parenchymal observations, such as rib fracture and pneumothorax were also noted. The sensitivity, specificity, and positive and negative predictive values of chest radiographs were calculated by accepting thoracic CT as the gold standard.

### Results

Among the 60 chest radiographs, 32 revealed a pathological density increase related to parenchymal injury, whereas 28 did not reveal findings indicative of parenchymal injury (Table). In 27 of the 32 patients in which parenchymal injury was detected with chest radiographs, parenchymal injury was confirmed by thoracic CT. The remaining 5 patients did not show any signs of parenchymal injury with thoracic CT, and 3 of them had hemothorax and 2 had chest wall hematomas. Among the 28 patients with negative findings of parenchymal injury according to chest radiographs, 12 were found to have parenchymal contusions based on thoracic CT, and one had accompanying laceration.

Considering thoracic CT findings the gold standard, the sensitivity of chest radiography in detecting parenchymal injury in patients with blunt trauma was 69%, the specificity was 76%, the positive predictive value was 84%, and the negative predictive value was 57%.

Of the 60 patients, 39 (65%) had lung parenchymal injuries (Figs. 1–3).

Among them, 37 had contusion (62%), 4 had laceration (7%), and 2 had hematoma (3%). The most common pathologies that accompanied the parenchymal injuries were rib fractures (84%), hemothorax (82%), and pneumothorax (73%), and 5 patients (8%) presented with pneumomediastinum. Mediastinal major vascular injuries, tracheobronchial injury, and diaphragmatic, esophageal, and other injuries were not observed. In 2 patients, solely lung parenchymal injury (isolated contusion) was detected without any accompanying thoracic wall or bone pathologies.

### Discussion

In multi-trauma patients, when injuries of the head and neck, spine, abdomen, or extremities are prominent, pathologies concerning the thorax may be overlooked, or if the initial chest radiograph is considered to be sufficient, parenchymal injuries may remain undetected. Mortality rates ranged from 14% to 40% in multi-trauma patients with lung contusion when accompanied by other organ injuries (4). In a study by Dee, the mortality rate of patients with isolated parenchymal injuries and no other chest injuries was 11%, whereas the rate increased to 22% in the presence of any other injury (5). Therefore, patients with contusion detected with chest radiography need to be followed up closely. Any change in the findings should be evaluated and a CT scan should be scheduled. In our study, we achieved full remission in the 2 patients with isolated parenchymal injury. Our mortality rate in patients with multiple organ injuries accompanying lung parenchymal injury (n = 39) was 21%.

Thoracic traumas can be classified as parenchymal and extra-parenchymal. Parenchymal traumas include contusion, laceration, hematoma, and torsion of pulmonary tissue. With the progression of those findings or as a

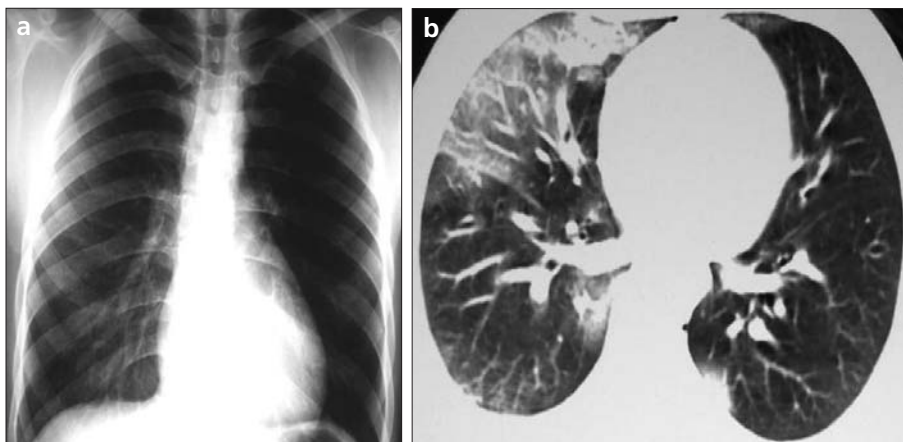
complication, respiratory distress syndrome, aspiration pneumonia, and atelectasis may occur. Contusion occurs as a result of the effect of direct pressure after a blunt trauma and is usually seen adjacent to solid structures like vertebrae, ribs, the liver, and the heart (6). In chest radiographs, lung contusion appears within the first 6–8 h following trauma as a non-homogenous density increase (4, 7). Radiographic findings may not be visible within the first few days. The contusion area becomes more difficult to visualize in cases of accompanying hemothorax, aspiration pneumonia, or atelectasis. Contusions are often seen as non-segmental, non-lobar, peripheral, and in the form of increased density on thoracic CT. It is more likely to detect contusions with thoracic CT than with chest radiography (8). In blunt traumas, contusions are reported in 17%–70% of cases (9–13). In our study, the rate of lung contusions in blunt thoracic traumas was 62%, and contusion was the major component (95%) of lung parenchymal injuries.

Lung laceration occurs more frequently with penetrating traumas, whereas it may occur in blunt traumas due to the direct effects of pressure on the thorax, the effects of rib fracture, sudden collapse of pulmonary tissue, or corresponding strokes in different positions. It is difficult to detect lacerations with chest radiography as they usually overlap accompanying contusion areas. Following trauma, the detection of a non-homogenous density increase, in addition to radiolucent air spaces, can be indicative of laceration. When lung contusion begins to resolve within 2–4 days of the trauma, lacerations become more visible in thoracic CT than in chest radiograph (13). A Swiss cheese appearance occurs if there are numerous small laceration areas inside the contusion region (14) (Fig. 2c). Hematomas are seen as well-defined, spherical or oval, homogenous increased densities, both with thoracic CT and chest radiography. In our study, the laceration rate was 7% and the hematoma rate was 3% due to blunt thoracic injury.

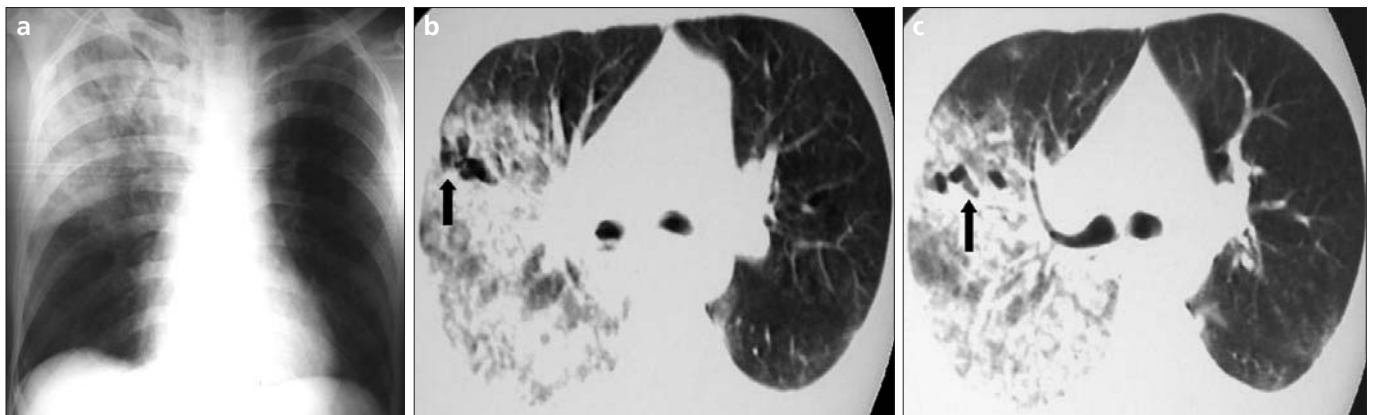
While evaluating the patient, one must keep in mind that there may be injuries of the lungs and mediastinum without any accompanying thorax wall damage. Additionally, as children and young patients have more flex-

Parenchymal injury in patients according to chest radiography and thoracic CT

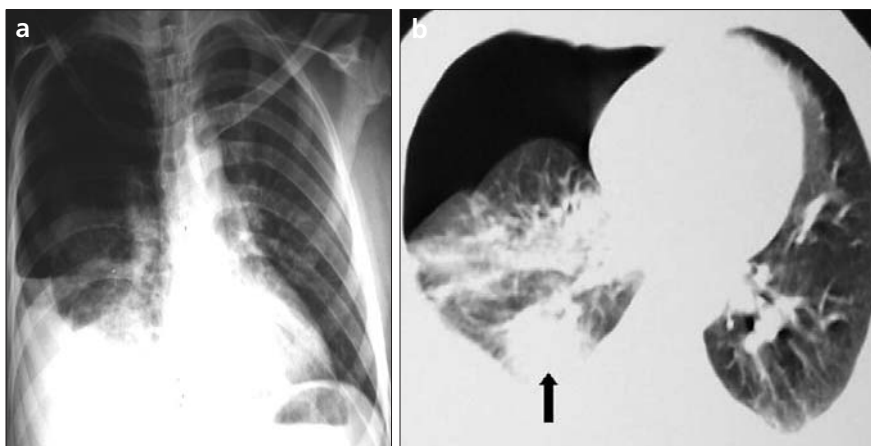
	Patients with parenchymal injury	Patients without parenchymal injury	Total
Chest radiography	32	28	60
Thoracic CT	39	21	60



**Figure 1. a, b.** On chest radiograph (a) there is no sign of parenchymal injury, whereas on axial thoracic CT image (b) at the parenchymal window, obtained following hemoptysis, non-homogenous increased densities, consistent with contusion, in the middle lobe of the right lung and bilateral posterior paraspinal regions are evident.



**Figure 2. a–c.** On chest radiograph (a) density increase consistent with contusion at the right lung's superior and middle zones is evident. Axial thoracic CT images (b, c) of the same patient at the parenchymal window, which were obtained following the chest radiograph, indicate a broad contusion area with laceration (arrow, b) and an additional Swiss cheese appearance (arrow, c) in the right lung.



**Figure 3. a, b.** On chest radiograph (a), air-fluid level (hemopneumothorax) and atelectasis is visible at the right side. Non-homogenous density increase within the atelectatic parenchyma at the right paracardiac region is also seen. On axial thoracic CT image (b) at the parenchymal window, a spherical hematoma (arrow) with homogenous density is seen at the posterior right lung.

ible chest walls, there may not be a rib fracture even if there is a lung injury (15). In our study, 2 patients who had isolated lung contusion without extra-parenchymal findings were 18 and 24 years of ages.

Fractures in the first 3 ribs portray a serious amount of energy transfer during the trauma and in this case there is a high risk of tracheobronchial, vascular, cardiac, and pulmonary parenchymal injury (4). Chest radiography can

be ineffective in evaluating such conditions. For that reason, use of thoracic CT when a rib fracture is detected in that region can prevent serious problems from being overlooked. As a matter of fact, among the 5 patients with fractures of the first 3 ribs in our study, 4 had lung contusion and 1 had accompanying laceration.

Some research has indicated a low sensitivity of chest radiography, compared to thoracic CT, in the detection of lung injuries in thoracic traumas (8, 16). In the present study, the sensitivity of chest radiography in detecting parenchymal injury was 69%, and the specificity was 76%. While chest radiographs of 28 patients were negative for lung parenchymal damage, we detected contusion in 12 of them using thoracic CT; thus, the false negativity rate of chest radiography was 43%. For that reason, we think that the indication for thoracic CT must be determined immediately for patients with severe thoracic trauma. It is not possible to determine early parenchymal injury signs using chest radiography and, moreover,

pathologies can be overlooked because of blind spots, like areas neighboring the diaphragm, or retrocardiac and paraspinal regions. Motion artifacts usually occur in traumatic patients, thus increasing the difficulty of evaluating the images and offering an explanation for the low specificity and high false negativity in detecting parenchymal injuries with chest radiography. Initial chest radiography obtained in chest trauma patients is also insufficient in the differential diagnosis of contusion, hemorrhage, laceration, hematoma, atelectasis, and hemothorax. In our study, among the 5 patients that we considered to have had lung parenchymal injury, according to their anteroposterior chest X-rays, 3 of them had rib fracture and hemothorax, and 2 had rib fracture and thoracic soft tissue hematomas on their thoracic CTs. These false positives were due to superimpositions on chest radiographs. Lateral images may reduce these superimpositions to a certain degree. As superimpositions on chest radiographs are avoided in thoracic CT, all thoracic structures can be evaluated in detail. Detection of these findings in

the early stage promotes effective treatment planning and positively affects the prognosis.

In conclusion, the sensitivity of anteroposterior chest radiography in detecting lung parenchymal injuries is low, with a high rate of false negativity. Therefore, we think that thoracic CT evaluation of patients with severe thoracic trauma, in the early stage, with the cooperation of emergency physicians and radiologists will be beneficial for diagnosis and treatment planning.

#### References

1. Jones KW. Thoracic trauma. *Surg Clin North Am* 1980; 60:957-981.
2. Battistella FD, Benfield JR. Blunt and penetrating injuries of the chest wall, pleura and lungs. *General thoracic surgery*, 5th ed. Philadelphia: Williams and Wilkins, 2000; 815-863.
3. Wisner D, Sturm J. Controversies in the fluid management of post-traumatic lung disease. *Injury* 1986; 17:295-300.
4. Mirvis SE. Diagnostic imaging of acute thoracic injury. *Semin Ultrasound CT MR* 2004; 25:156-179.
5. Dee PM. The radiology of the chest trauma. *Rad Clin North Am* 1992; 30:291-306.
6. Gavelli G, Canini R, Bertaccini P, et al. Traumatic injuries: imaging of thoracic injuries. *Eur Radiol* 2002; 12:1273-1294.
7. Kerns SR, Gay SB. CT of blunt chest trauma. *AJR Am J Roentgenol* 1990; 154:55-60.
8. Schild HH, Strunk H, Weber W, et al. Pulmonary contusion CT vs plain radiograms. *J Comput Assist Tomogr* 1989; 13: 417-420.
9. Cohen MC. Pulmonary contusion: review of the clinical entity. *J Trauma* 1997; 42:973-979.
10. Greene R. Lung alterations in thoracic trauma. *J Thorac Imaging* 1987; 2:1-11.
11. Mirvis SE, Templeton P. Imaging in acute thoracic trauma. *Semin Roentgenol* 1992; 27:184-210.
12. Tocino I, Miller MH. Computed tomography in blunt chest trauma. *J Thorac Imaging* 1987; 2:45-49.
13. Wagner RB, Crawford WO Jr, Schimpf PP. Classification of parenchymal injuries of the lung. *Radiology* 1988; 167:77-82.
14. Mirvis SE. Imaging of acute thoracic injury: the advent of MDCT screening. *Semin Ultrasound CT MR* 2005; 26:305-331.
15. Shorr RM, Crittenden M, Indeck M, et al. Blunt thoracic trauma: analysis of 515 patients. *Ann Surg* 1987; 206:200-205.
16. Primack SL, Collins J. Blunt nonaortic chest trauma: radiographic and CT findings. *Emerg Radiol* 2002; 9: 5-12.